

Achalasia: A Tough Problem to Swallow

Jeremy P. Parcels, M.D.

Grand Rounds

University of Kentucky

Department of Surgery

Objectives

- Review the pathology of achalasia
- Discuss the workup of achalasia
- Discuss the current options for the management of achalasia
- Describe a new development in the treatment of achalasia

History of achalasia

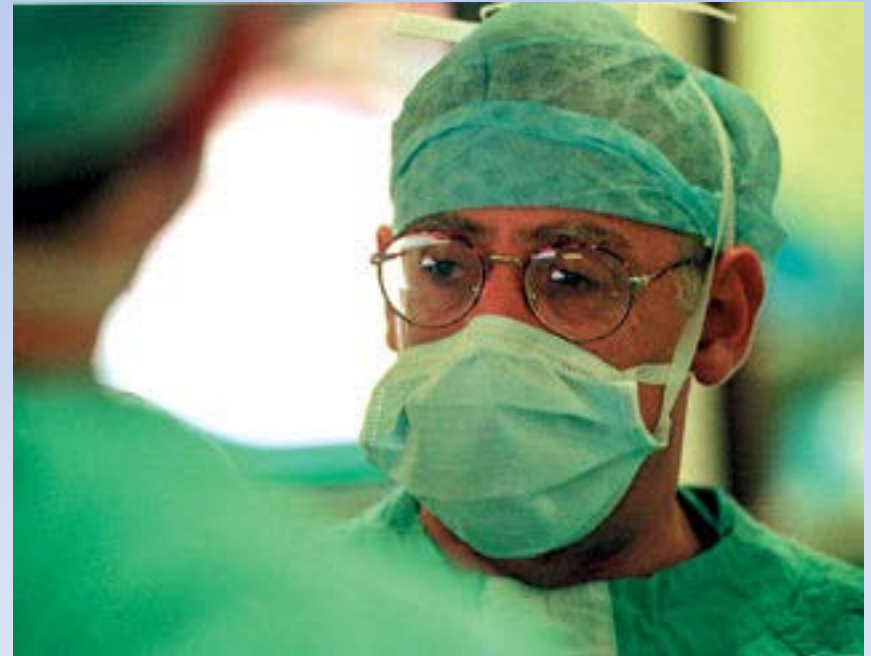- First described by Sir Thomas Willis in 1672
- The article was titled *Pharmaceutice rationalis sive diatribe de medicamentorum operationibus in humano corpore*
- He described a patient who was unable to swallow liquids
- His therapy was a carved whalebone with a sponge at the tip which was used to dilate the narrowed esophagus

History of achalasia

- In 1913 Ernest Heller performed the first surgical intervention for achalasia and the procedure still bears his name
- It was not actually called achalasia until a 1927 article by Arthur Hurst
 - *The treatment of achalasia of the cardia: so-called 'cardiospasm'*
 - Achalasia is Greek for lack of relaxation
- Ellis et al described the first transthoracic approach in 1958

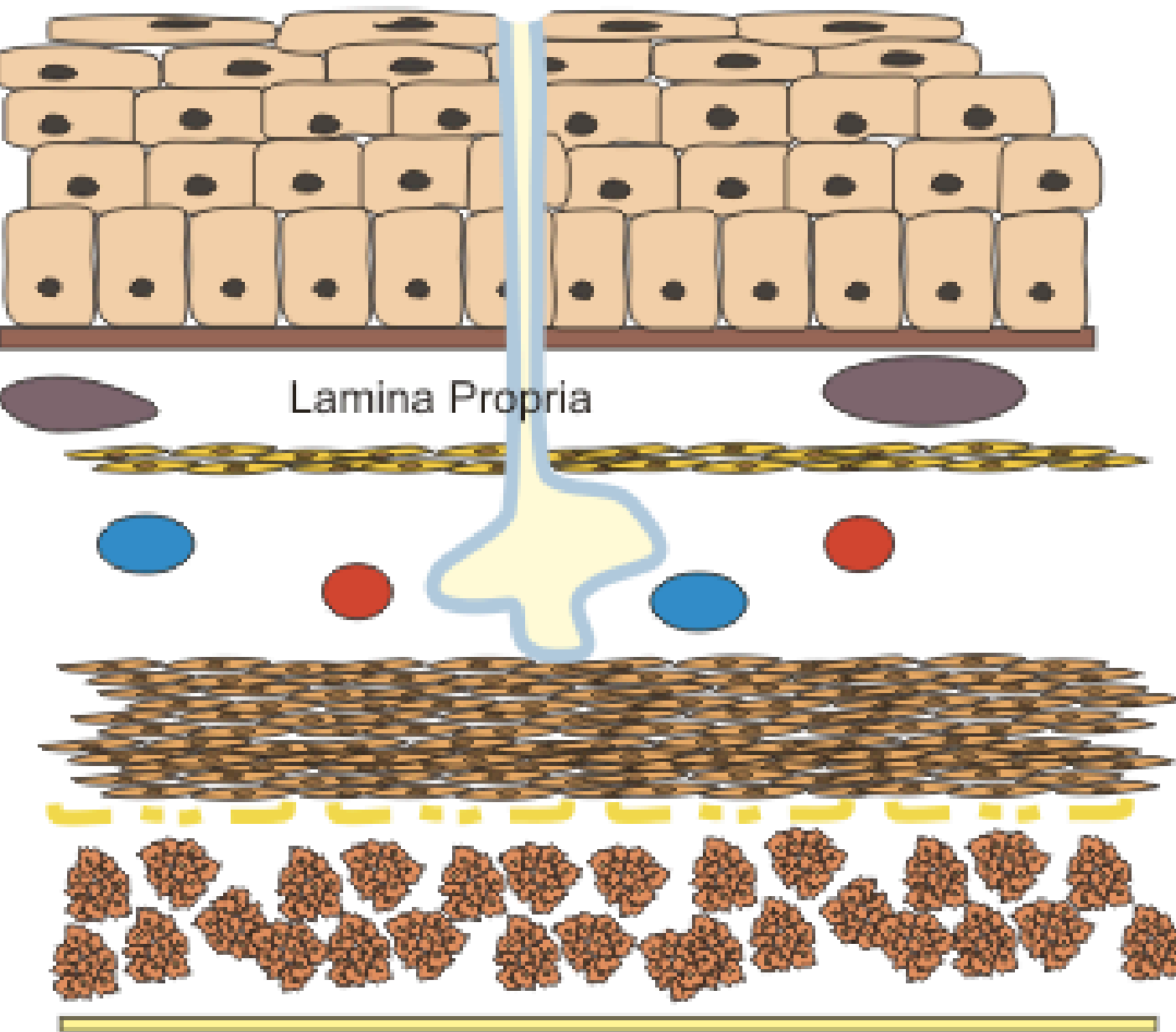
History of achalasia

- The first laparoscopic Heller myotomy by Sir Alfred Cuschieri in 1991



What is achalasia?

- Aperistalsis of the esophageal body
- Hypertonic lower esophageal sphincter
- It is due to a degenerative condition of the neurons of the esophageal wall
- It is the second most common benign disorder of the esophagus requiring surgical intervention



Stratified Squamous Epithelium

Lymphoid Tissue

Lamina Propria

Muscularis Mucosa

Blood Vessels & Glands

Circular Muscle

Neural Plexus

Longitudinal Muscle

Histopathology of achalasia

- Histologic examination shows a decrease in the neurons of the myenteric plexuses (Auerbach's plexus)
- There is a preferential decrease in the nitric oxide producing cells
 - These contribute to LES relaxation
- There is a relative sparing of the cholinergic neurons
 - responsible for maintaining LES tone

Histopathology of achalasia

- The loss of these inhibitory neurons leads to an increased resting tone in the LES
- It also leads to aperistalsis of the esophagus

Etiology of achalasia

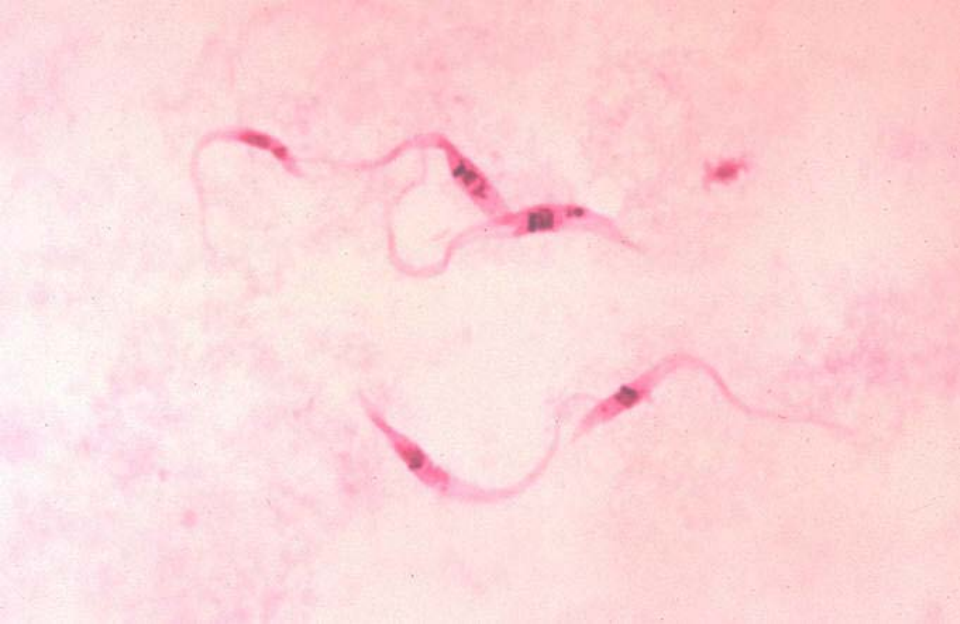- While primary achalasia is considered idiopathic, there are a few theories
- HLA DQw1 has been shown to be associated with achalasia and the presence of anti-myenteric antibodies
 - This has led some to propose that achalasia may be an autoimmune disorder

Etiology of achalasia

- Some have shown an association with chronic herpes zoster or measles
- T-cell evaluation of patients with achalasia has shown a reactivity to HSV-1, which may suggest that achalasia can be due to an HSV-1 infection

Etiology of achalasia

- Secondary achalasia can be due to Chagas disease
- Chagas disease occurs mainly in Central and South America
- It is due to an infection by the protozoan parasite *Trypanosoma cruzi* which is carried by *Rhodnius prolixus*
- Infection results in the loss of ganglion cells in Auerbach's plexus



Etiology of achalasia

- When evaluating patients for achalasia, it is important to rule out the possibility of malignancy, which can mimic achalasia
- Things that may suggest malignancy include:
 - Presence of symptoms for less than six months
 - Onset after age 60
 - Excessive weight loss
 - Difficultly passing endoscope past GEJ

Etiology of achalasia

- Other disease have been associated with achalasia-like motor abnormalities:
 - Amyloidosis
 - Eosinophilic gastroenteritis
 - Sarcoidosis
 - Neurofibromatosis
 - MEN type 2B
 - Chronic idiopathic intestinal pseudo-obstruction
 - Fabry disease
 - Juvenile Sjögren's syndrome

Achalasia

- Has an annual incidence of 1.6 per 100,000 people
- The relative infrequency of the disease has made it more difficult to study in comparison to more common disease processes
- Occurs equally in men and women
- Usually occurs in individuals age 20-50

Clinical manifestations of achalasia

- Most common symptom of achalasia is dysphagia
 - Food > 90%
 - Liquids > 80%
- Other dysmotility disorders of the esophagus may also have dysphagia, but not with the frequency of achalasia

Clinical manifestations of achalasia

- Mild weight loss (usually < 10 kg)
- Regurgitation
- Chest pain
- Heartburn
- Patients may sense a lump in their throat (globus)
- Hiccups

Clinical manifestations of achalasia

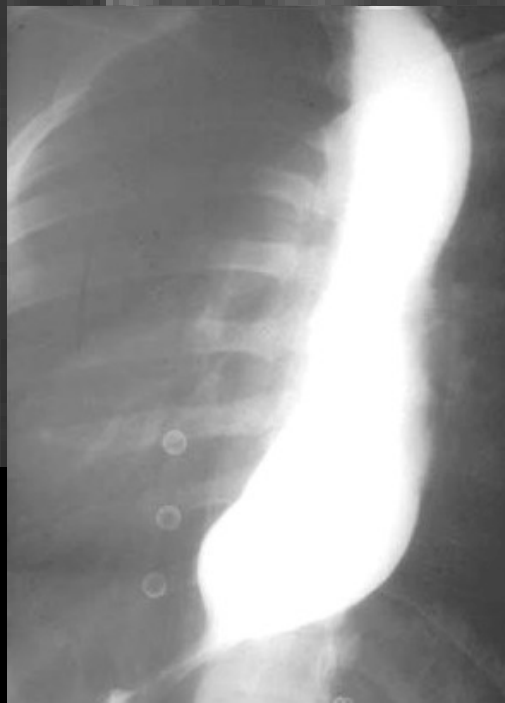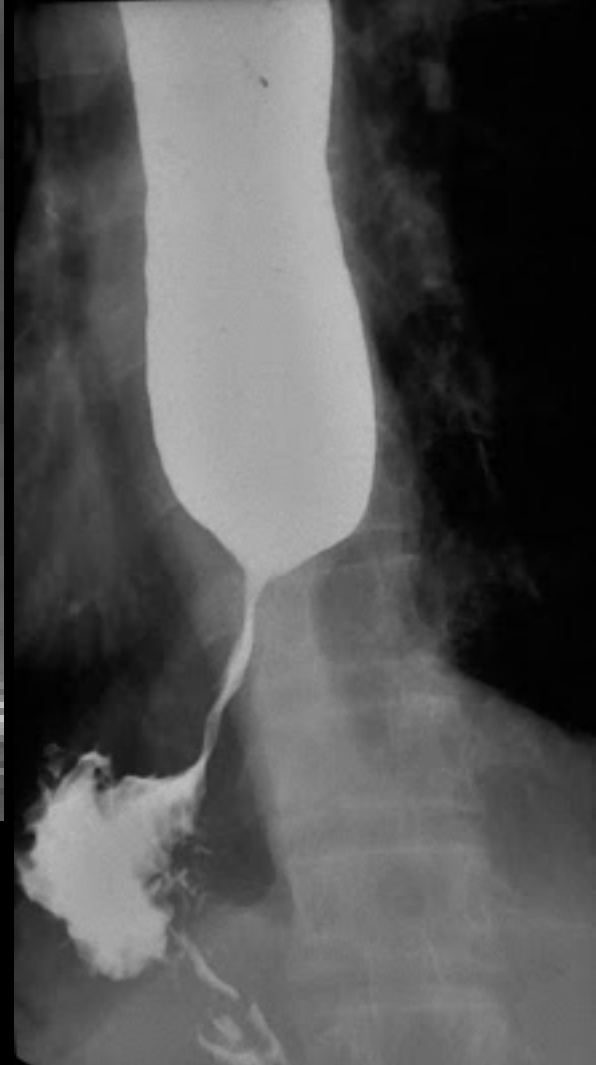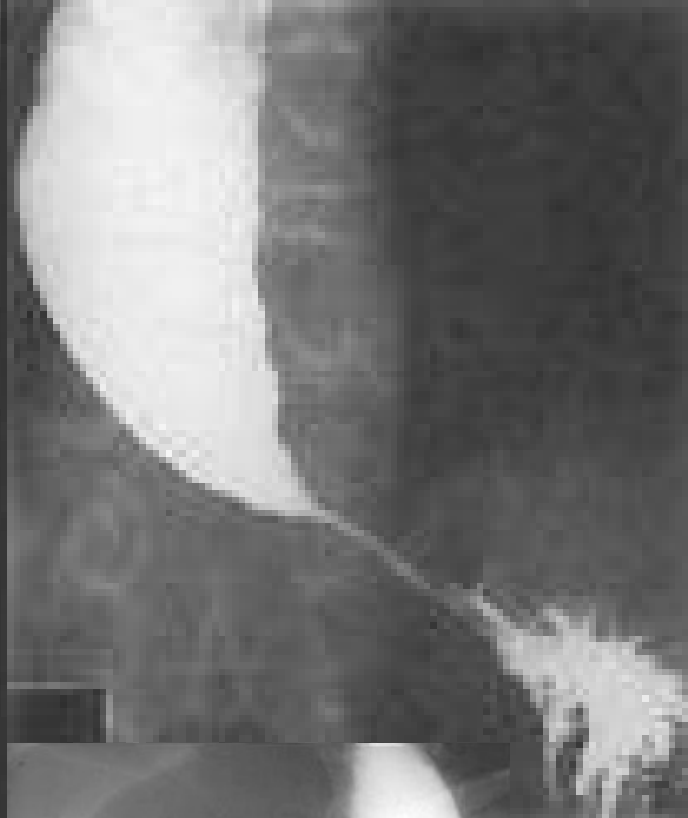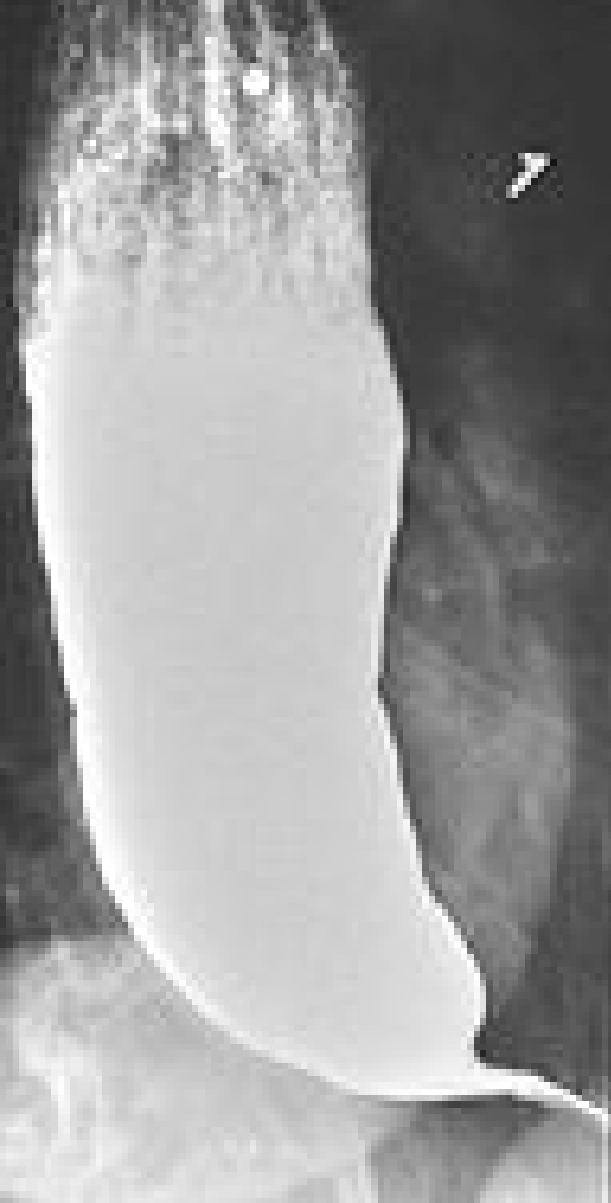- Patients may take multiple steps to overcome their disease process
 - Eating more slowly
 - Using certain maneuvers like lifting their neck or throwing their shoulders back

Diagnosis of achalasia

- Onset of symptoms is slow and gradual. The average time between onset of symptoms and diagnosis is over four years.
- In patients with suspected achalasia, there are three important tools in diagnosing achalasia
 - Barium swallow
 - Endoscopy
 - Manometry

Barium swallow

- Barium swallow is an excellent tool in the diagnosis of achalasia
- Classic appearance shows a dilated esophagus which tapers to a classic “bird beak” appearance
- The diagnostic accuracy of a barium swallow was 95% in one study



Manometry – Three classic findings

- Elevated resting LES pressure (often above 45 mmHg)
- Incomplete LES relaxation
 - The LES should drop to <8 mmHg above gastric pressure)
 - In achalasia LES relaxation in response to a swallow may be incomplete or absent

Manometry – Three classic findings

- Aperistalsis of the esophagus.
 - A swallow may have no corresponding esophageal contractions.
 - Alternatively, there may be simultaneous contractions.
 - While the contractions are classically low amplitude, there is a subset of patients who have high amplitude, simultaneous contractions. This has been termed "vigorous" achalasia.

Endoscopy

- All patients with suspected achalasia should undergo endoscopy to rule out malignancy
- On entering the esophagus, it is usually large and will potentially have retained food
- While the LES is does not open spontaneously, it can be passed with gentle pressure

Diagnosis of achalasia

- Additional modalities such as CT scan or endoscopic ultrasound (EUS) can be helpful in the workup of a patient for achalasia if another cause is suspected (such as malignancy)

Treatment options

- Medical therapy with calcium channel blockers or nitrates
- They are taken 10-30 minutes before meals
- While they have been shown to have moderate success, they require the patient to take them perpetually
- They are not recommended as first-line therapy

BOTOX

- Botulinum neurotoxin type A
- Inhibits the release of acetylcholine
- The idea for the use of BOTOX came from an understanding of the pathophysiology of achlasia
- By blocking the release of Ach from the presynaptic channels in the ganglia of Auerbach's plexus, the theory is that the balance of neurotransmitters is restored

BOTOX

- Injection is done in the area of the lower esophageal sphincter (LES)
- It is administered endoscopically
- The standard technique is to inject 1 mL (20 to 25 units BT/mL) into each of four quadrants approximately 1 cm above the Z-line.
- Complications include:
 - Mediastinitis
 - Esophageal mucosal ulceration
 - Pneumothorax

BOTOX

- In attempts to be more precise, EUS has been used to determine the location of the LES for injection
- Wehrmann et al described using double-channel endoscopy for the purpose of having simultaneous manometry. They reported a slightly more durable effect.

BOTOX

- BOTOX has the downside of not being as effective as other interventions
- While studies have reported symptomatic relief as high as 90% after a few months, the effects generally fall to 50% or lower at one year and continue to diminish after that

BOTOX

- Additionally, there is evidence to suggest that subsequent injections will not be as successful as initial injections
- Botulinum toxin antibodies have been isolated and are thought to be the reason for the diminishing response in subsequent applications.
- A couple of predictors of favorable outcome have been shown:
 - Older age
 - Presence of vigorous achalasia.

BOTOX

- Another major drawback to the use of BOTOX is that it has a negative impact on future surgical intervention
- Horgan et al reported that the operation was more technically difficult
 - Higher difficulty identifying the submucosal plane
 - Higher incidence of mucosal laceration
- The current consensus on BOTOX is that it should only be used on patients who are not fit for other interventions

Pneumatic dilation

- Considered the most effective nonsurgical treatment of achalasia
- Involves passing the pneumatic device to the LES, using both endoscopy and fluoroscopy to properly place the balloon
- The balloon is inflated to a pressure between 7 to 15 psi
- Patients are usually observed for six hours and then discharged home



Copyright © 2006 Boston Scientific Corporation or its affiliates. All Rights Reserved.

Pneumatic dilation

- *Endoscopic and surgical treatments for achalasia: a systematic review and meta-analysis*
 - Article from UCSF by Campos et al who reported an initial improvement of symptoms in 84.8% of patients after dilation.
- At 36 months this number had decreased to 58.4%.
- As with BOTOX, subsequent interventions will have diminishing success rates

Pneumatic dilation

- The two best predictors of success:
 - Post-dilation pressure (or some report the difference between pre- and post-dilation pressures)
 - Older age
- The biggest concern with pneumatic dilation is esophageal perforation, which has been reported to be as low as 1.6% while other studies have reported an incidence of around 10% (one study reported 21% perforation rate)

Pneumatic dilation

- Additionally, Smith et al reported higher complication rates during Heller myotomy for patients who had undergone endoscopic intervention (study included patient receiving pneumatic dilation and/or BOTOX injections)
 - 9.7% vs 3.6%

Heller myotomy

- First described by Ernest Heller in 1913 where he used an abdominal approach to perform an anterior and posterior esophagomyotomy
- Surgical therapy now involves usually performing only an anterior myotomy, via either abdominal or thoracic approach
- In addition to laparoscopic myotomy, thoracoscopic myotomy has also been described
- Thoracic approach does have certain drawbacks

Heller myotomy

- At this point in time, laparoscopic myotomy is considered the standard operation
- When compared to open techniques, similar rates of complications with much shorter hospital stay and recovery times

Heller myotomy vs pneumatic dilation

- With reported success rates of around 90%, Heller myotomy has generally been considered to be superior to dilation
- In 1989, Csendes et al performed a RCT looking at Heller myotomy and pneumatic dilation
 - 39 pts with myotomy (open)
 - 42 pts with pneumatic dilation
 - Two patients receiving dilation had perforation
 - At five years, the surgical group had 98% rate of either no dysphagia or mild dysphagia compared to 73% of the patients receiving dilation

Heller myotomy vs pneumatic dilation

- In 2006, Vela et al performed a retrospective comparison of myotomy vs dilation
 - At six years, myotomy had a higher success rate at 57% compared to 44%
 - Success was defined as dysphagia or regurgitation less than three times per week
 - Of note, 36% of the patients who underwent myotomy who were considered not a success were due to having reflux symptoms compared to 4% with the pneumatic dilation group

Heller myotomy vs pneumatic dilation

- Article from NEJM in May of 2011: *Pneumatic dilation versus laparoscopic Heller's myotomy for idiopathic achalasia*
- Prospective RCT looking at 201 pt over 43 months
 - 95 pts with dilation vs 106 receiving myotomy with Dor fundoplication
 - Showed success rates at one year of 93% for LHM and 90% for pneumatic dilation
 - Showed success rates at two years of 90% for LHM and 86% for pneumatic dilation
 - No statistical significance

Heller myotomy

- In performing Heller myotomy, there are a few important questions to consider...
- To do a fundoplication?
- If so, what kind of fundoplication?
- What to do with the sigmoid esophagus?
- Length of myotomy?
- Any benefit to the robot?

To funduplicate, or not to funduplicate that is the question...



To fundoplicate, or not to fundoplicate that is the question...

- *Objective analysis of gastroesophageal reflux after laparoscopic heller myotomy: an anti-reflux procedure is required*
 - Article from *Surgical Endoscopy* from Jan 2005
 - Burpee et al, St. Michael's Hospital, Univ of Toronto
- Looked at 50 pts receiving Heller myotomy without fundoplication

To funduplicate, or not to funduplicate that is the question...

- 30% of pts complained of significant heartburn
- 24 hr pH probe or endoscopy demonstrated that **60%** of pts had significant reflux
- “Objective analysis reveals an unacceptable rate of gastroesophageal reflux in laparoscopic Heller myotomy without an antireflux procedure. We therefore recommend performing a concurrent antireflux procedure.”

To funduplicate, or not to funduplicate that is the question...

- *Heller myotomy versus Heller myotomy with Dor funduplication for achalasia: a prospective randomized double-blind clinical trial*
 - 2004 paper from *Annals of Surgery* by Richards et al from Vanderbilt
- Prospective, double-blind RCT
- 43 pts enrolled

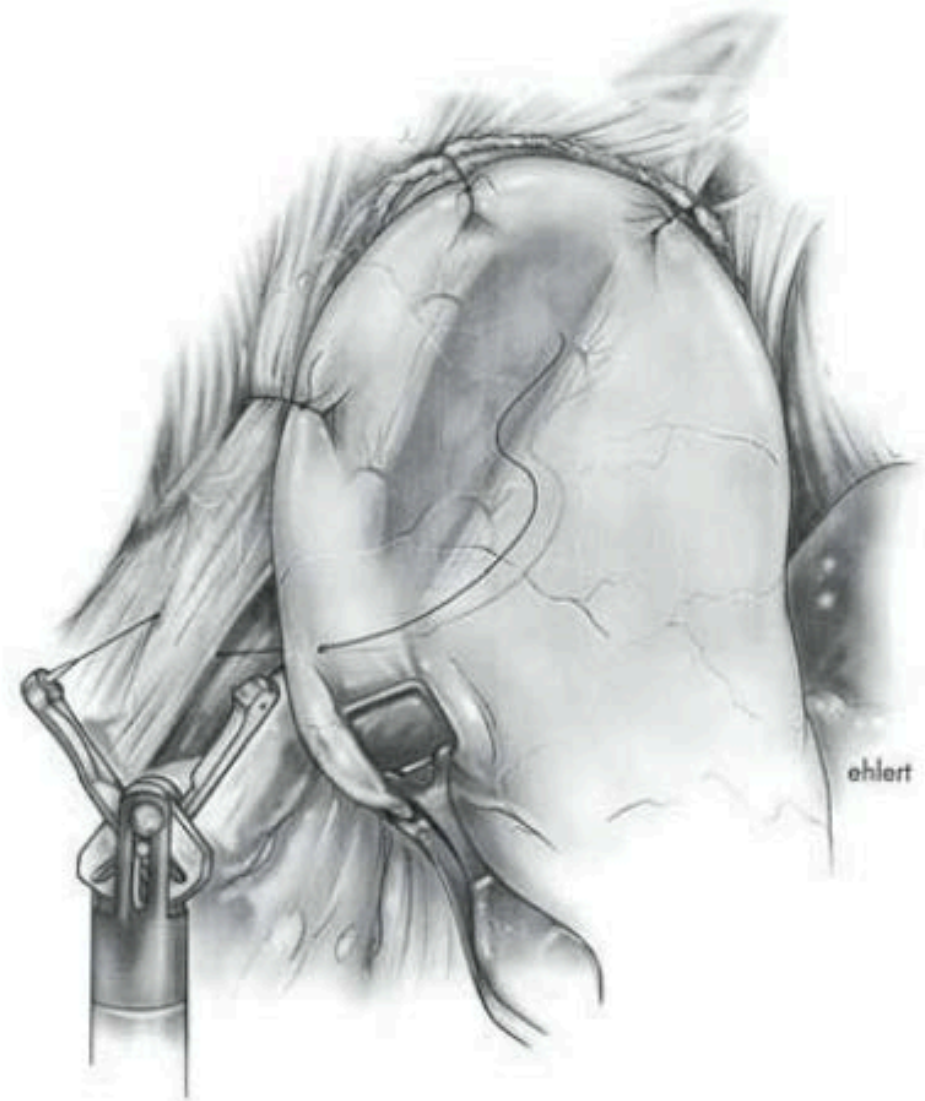
To fundoplicate, or not to fundoplicate that is the question...

- Pathologic GER occurred in 10 of 21 patients (47.6%) after Heller and in 2 of 22 patients (9.1%) after Heller plus Dor ($P = 0.005$).
- Manometry and EGD were performed at 6 months post-op.
- No significant difference was observed in surgical outcome between the 2 techniques with respect to postoperative lower-esophageal sphincter pressure or postoperative dysphagia score.

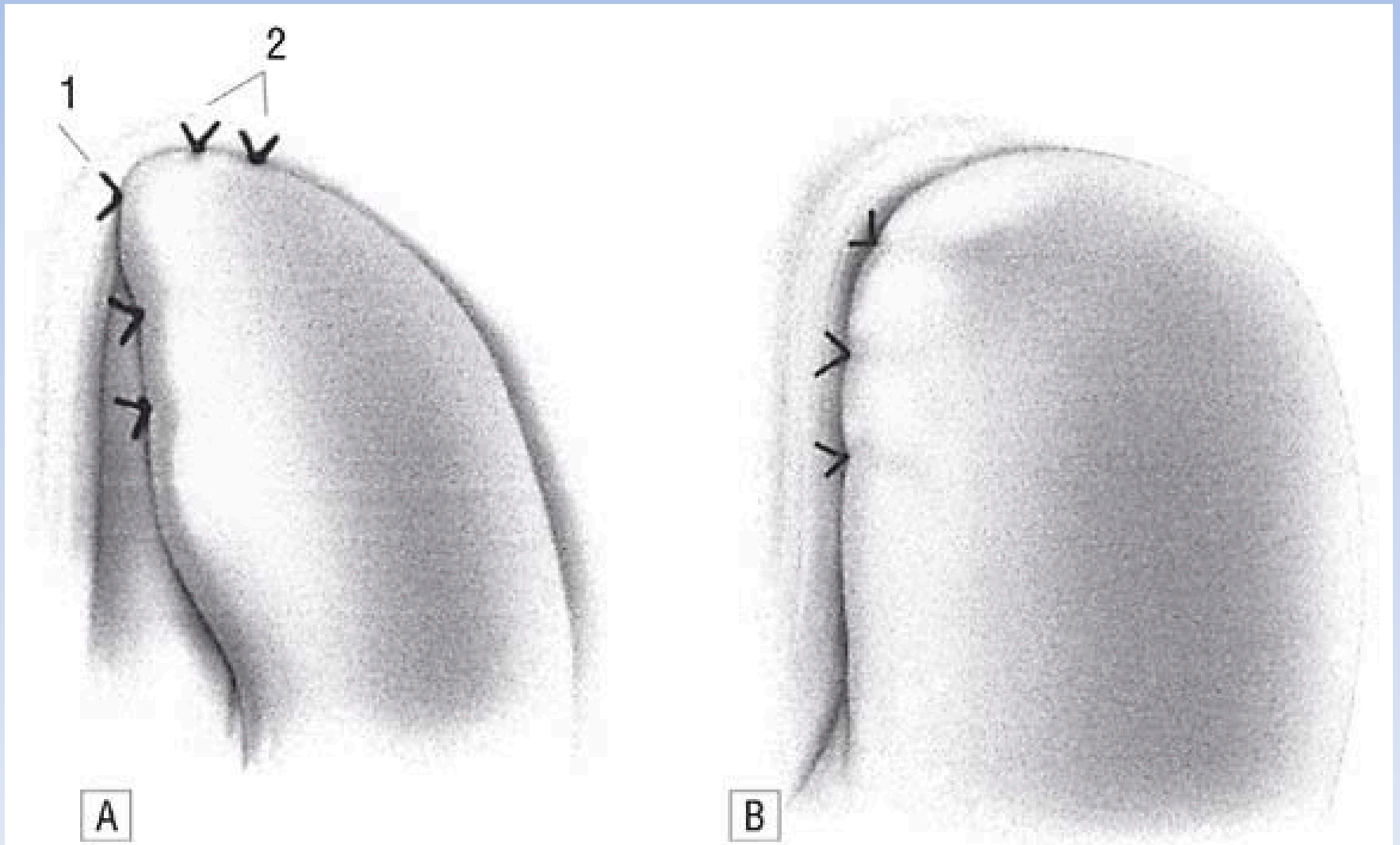
Dor vs Toupet fundoplication

- Dor fundoplication is an anterior 180 degree wrap
- Toupet fundoplication is a posterior 270 degree wrap

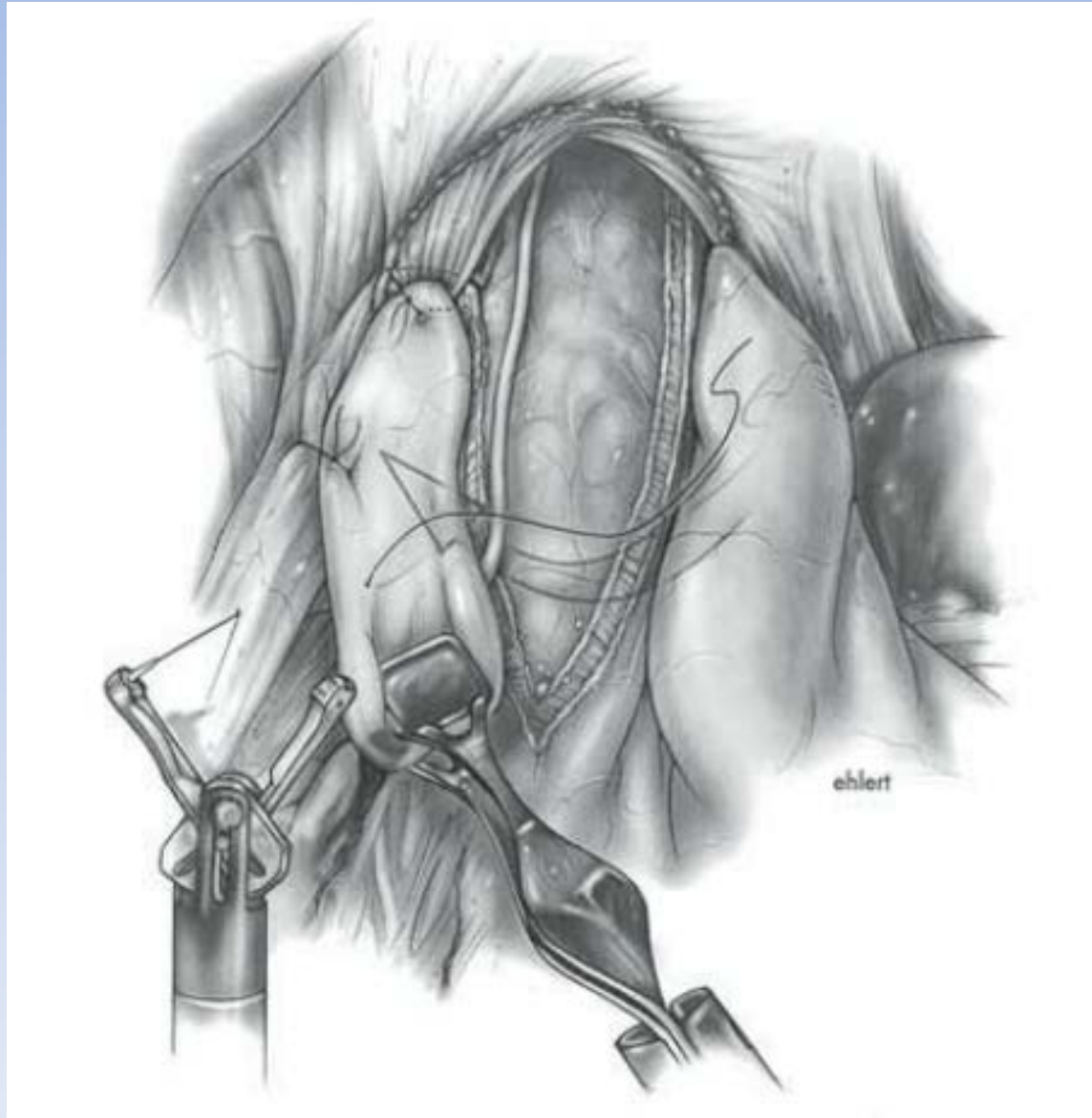
Dor fundoplication



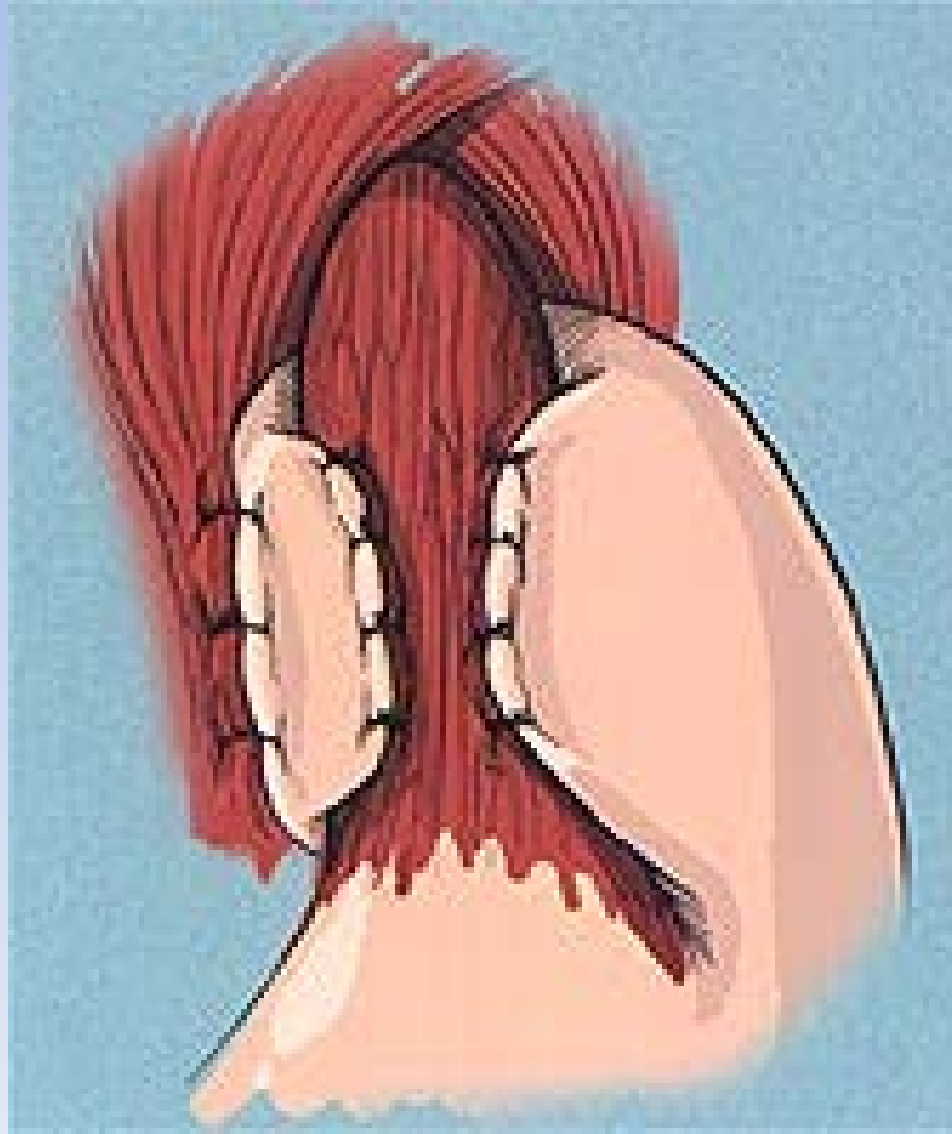
Dor fundoplication



Toupet fundoplication



Toupet fundoplication



Dor vs Toupet fundoplication

- *Preoperative lower esophageal sphincter pressure affects outcome of laparoscopic esophageal myotomy for achalasia*
 - 2004 article from the *Journal of Gastrointestinal Medicine*
 - Article by Arain et al from Keck School of Medicine (USC)
- Retrospective review looking at 64 patients
 - 41 received Heller plus Dor fundoplication
 - 23 received Heller plus Toupet fundoplication

Dor vs Toupet fundoplication

- They showed no significant difference in outcome
 - Looked at dysphagia
 - Looked at GER and use of PPIs
- To date, there has been no randomized controlled trial comparing the two procedures

Hey, what about a Nissen fundoplication?

- *Randomized controlled trial of laparoscopic Heller myotomy plus Dor fundoplication versus Nissen fundoplication for achalasia: long-term results*
 - 2008 article from *Annals of Surgery*
 - By Rebecchi et al from Turin, Italy
 - RCT
- Looked at 144 pts with 6 lost to follow-up
 - 71 received Heller plus Dor fundoplication
 - 67 received Heller plus Nissen fundoplication

Hey, what about a Nissen fundoplication?

- Found difference of GER of 5.6% to 0% in Dor vs Nissen (not statistically significant)
- Found difference of dysphagia rate of 2.8% vs 15% (statistically significant)
- Concluded that Nissen fundoplication was inferior to Dor fundoplication in regards to Heller myotomy

Achalasic sigmoid esophagus

- Markedly dilated esophagus with tortuous, angulated shape
- Previously believed that this would require esophagectomy or at the very least preclude fundoplication.

Achalasic sigmoid esophagus

- In 2004 Mineo and Pompeo published results showing 14 patients with achalasic sigmoid esophagus who underwent Heller myotomy with Dor fundoplication
 - Patients did very well esophagus returned to normal size
- In 1999, Patti et al showed that esophageal dilation or shape did not affect the operation and that all their patients were successfully treated with Heller myotomy and Dor fundoplication.


Length of myotomy

- Often quoted as needing 5 cm of esophageal myotomy with 1 cm of myotomy onto the cardia
- *Long-term outcomes confirm the superior efficacy of extended Heller myotomy with Toupet fundoplication for achalasia*
 - 2007 article from *Surgical Endoscopy*
 - By Wright et al from University of Washington
 - Retrospective review

Length of myotomy

- They looked at performing an extended myotomy of at least 3 cm in length
- They reported a lower dysphagia severity score in the group receiving the extended myotomy.
- There were fewer reinterventions for dysphagia (5% vs 10%)
- No significant difference in other areas
 - Heartburn
 - Esophageal acid exposure
 - LES pressure

What about the robot?



What about the robot?

- *Laparoscopic Heller myotomy for achalasia facilitated by robotic assistance*
 - Galvani et al from University of Illinois, Chicago
 - 2006 article from *Surgical Endoscopy*
- Showed it to be safe and effective

What about the robot?

- *How does the robot affect outcomes? A retrospective review of open, laparoscopic, and robotic Heller myotomy for achalasia*
 - Oct 2011 article from *Surgical Endoscopy*
 - By Shaligram and Oleynikov from University of Nebraska Medical Center

What about the robot?

- The article reported slightly lower rates of mortality, morbidity, ICU admission, and length of stay (none of which were statistically significant)
- It did show a higher average cost (\$9415 vs \$7441) (which was statistically significant)

What about the robot?

- Dmitry Oleynikov, MD
(my future boss)



Recurrent dysphagia after Heller myotomy

- Concern for malignancy should be at the top of the list
- Swedish study reported the risk of esophageal cancer after diagnosis was increased 16-fold.
- Cancer was diagnosed an average of 14 years after the initial diagnosis of achalasia was made.

Recurrent dysphagia after Heller myotomy

- A study from the Netherlands included 448 patients with achalasia
- Esophageal cancer developed in 15 patients (3.3%) at a mean of 13 years after initial diagnosis.
- It can be squamous cell type or adenocarcinoma, but squamous cell type is more common

Recurrent dysphagia after Heller myotomy

- A retrospective study from Israel from 1993 looked at 162 patients and showed no cases of subsequent esophageal cancer. The authors suggested that earlier intervention may have contributed to this.
- 2006 guidelines from the Society of Gastrointestinal Endoscopy says there is not evidence to warrant surveillance endoscopy

Recurrent dysphagia after Heller myotomy

- One option for recurrent dysphagia after Heller myotomy is repeat myotomy
 - Considered a much more challenging operation as you have to go through previous scar to perform myotomy
- An alternative is to perform distal esophagectomy and proximal gastrectomy
- Pneumatic dilation after Heller myotomy has so far been shown to be relatively safe and effective

A new approach to achalasia

- In 2007, while still at UTMB in Galveston, Tx, Jay Pasricha proposed an alternative method for the treatment of achalasia...

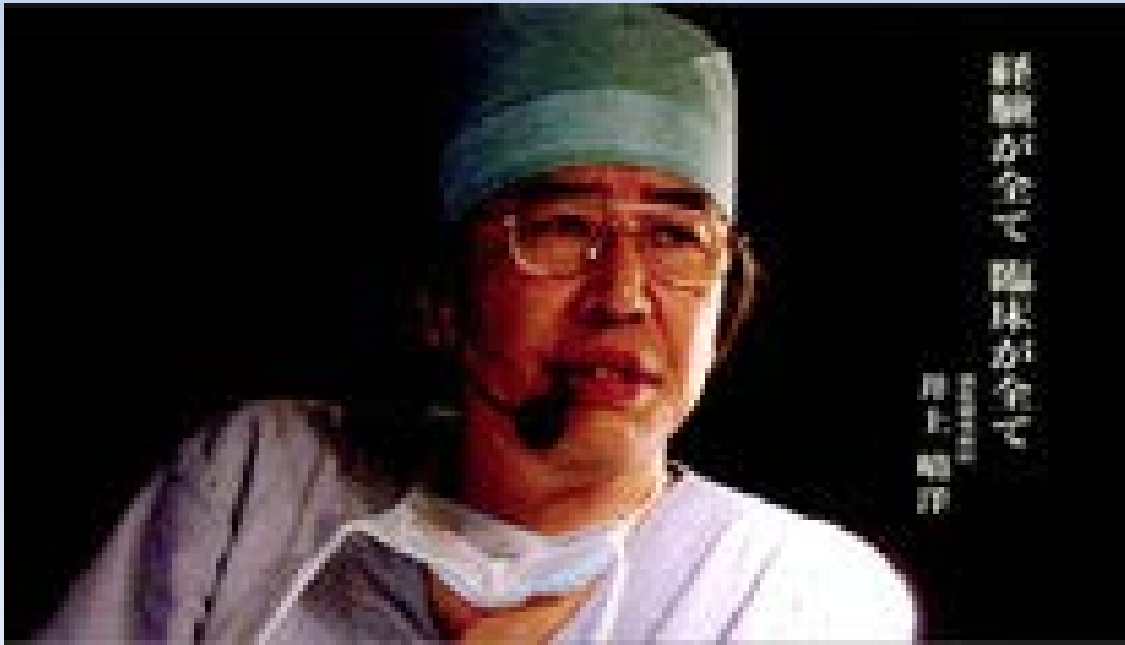

A new approach to achalasia

- *Submucosal endoscopic esophageal myotomy: a novel experimental approach for the treatment of achalasia*
 - Published in *Endoscopy*, 2007
- It has also been referred to as POEM: Peroral endoscopic myotomy
- It is considered a form of NOTES

A new approach to achalasia

- The leading expert in this technique is Dr. Haruhiro Inoue, from Showa University Northern Yokohama Hospital in Japan.
- He has performed over 100 procedures



A new approach to achalasia

- Start by entering the submucosal space approximately 15 cm above the GE junction
- Uses an endoscope with a special transparent cap
- Using a solution of saline with indigo dye, a tunneled dissection is carried distally to about 2 cm past the GE junction
- Then, myotomy is begun starting 10 cm proximal to GE junction

A new approach to achalasia

- Myotomy is carried distally down to 2 cm past the GE junction
- Myotomy only takes the inner circular fibers while leaving the outer longitudinal fibers intact
- At the end of the procedure, the scope is removed from the submucosal tunnel and the entry site is closed with endoscopic clips

A new approach to achalasia

- This past May at the 2011 Digestive Disease Week (DDW), Dr. Inoue presented a series of 100 consecutive patients
- Average myotomy of 14 cm
- Average decrease in resting LES pressure from 26.8 mmHg to 12.6 mmHg
- Average operating time of 113 minutes
- Mean hospital stay of 5.9 days
- No major complications

A new approach to achalasia

- He has successfully performed the procedure on patients who underwent previous operative intervention and others with sigmoid esophagus
- So far, he has reported excellent short term results

Concerns about endoscopic submucosal myotomy

- No long-term data
- Leaving the outer longitudinal muscle intact
- This procedure could make future surgical interventions more difficult

Summary

- Achalasia is a process that affect the myenteric plexus of the esophagus leading to high resting LES pressures and esophageal aperistalsis
- Medical therapy is pretty ineffective
- BOTOX should be reserved for patients who are not able to undergo other interventions
- Pneumatic dilation is effective, but has the risk of perforation

Summary

- Laparoscopic Heller myotomy has excellent results
- Should be accompanied by either Dor or Toupet fundoplication (not a Nissen)
- The myotomy should be at least 5 cm on the esophagus to 2 cm on the stomach, and possibly longer
- The robot may have a role in the future moving forward

Summary

- Laparoscopic Heller myotomy has excellent results
- Should be accompanied by either Dor or Toupet fundoplication (not a Nissen)
- The myotomy should be at least 5 cm on the esophagus to 2 cm on the stomach, and possibly longer

Summary

- The robot may have a role in the future moving forward
- Submucosal endoscopic myotomy definitely shows promise, but we lack long-term results and comparative studies to make definitive statements

Summary

- Special thanks to Dr. Scott Roth and Jim Hoskins

Questions?

